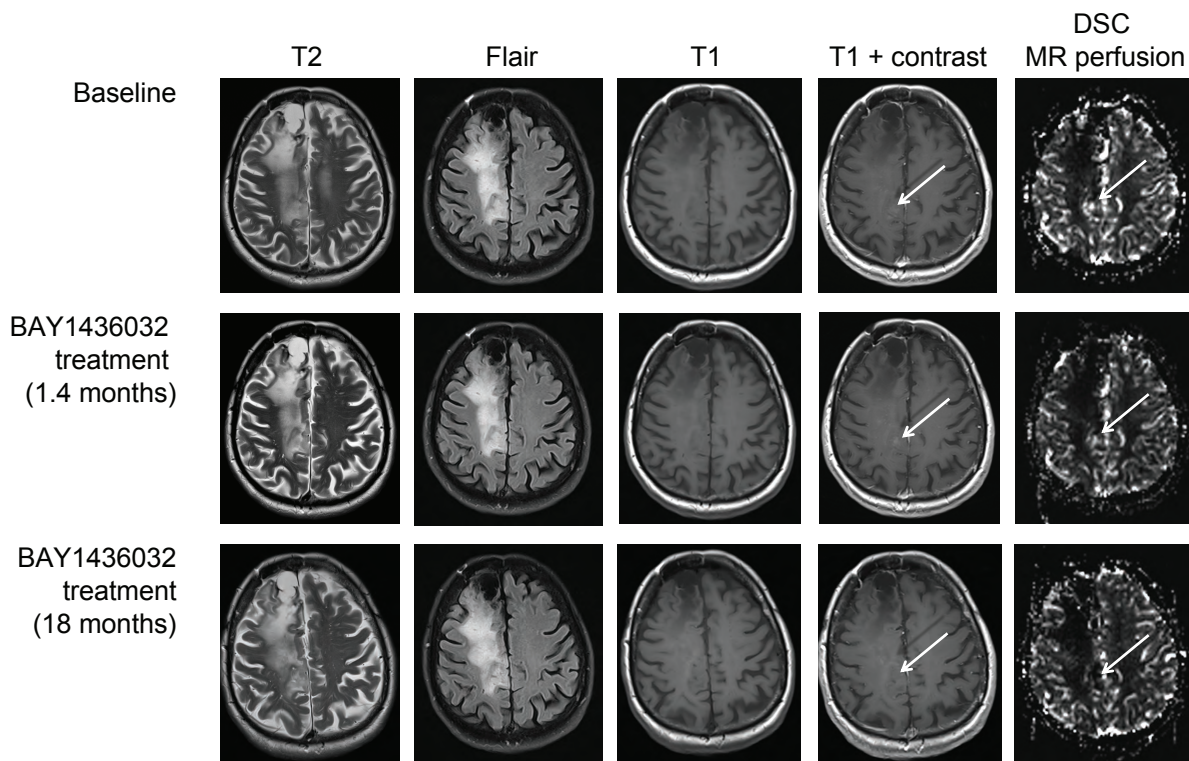


## SUPPLEMENTARY FIGURE 2



### Supplementary Figure S2. Tumor scans.

MRI scans from a subject with oligodendroglioma taken during screening (baseline) and again after 1.4 months and 18 months of BAY1436032 treatment at 1500 mg BID. By the time of data cutoff, the subject had experienced a best response of SD, ongoing PFS of 4.1 months, and a maximal tumor decrease of 36% (which had occurred after approximately 4 months of treatment). As of August 2020, the subject has been on treatment for a little over 2 years and was still taking study drug. The size of the enhancing lesion at baseline was 1.3 x 1.5 cm (perpendicular measurements). It was visible on > 2 axial slices and had clearly defined margins. It was therefore defined as measurable.

BID, twice-daily; DSC, dynamic susceptibility contrast; MRI, magnetic resonance imaging; PFS, progression-free survival; SD, stable disease.