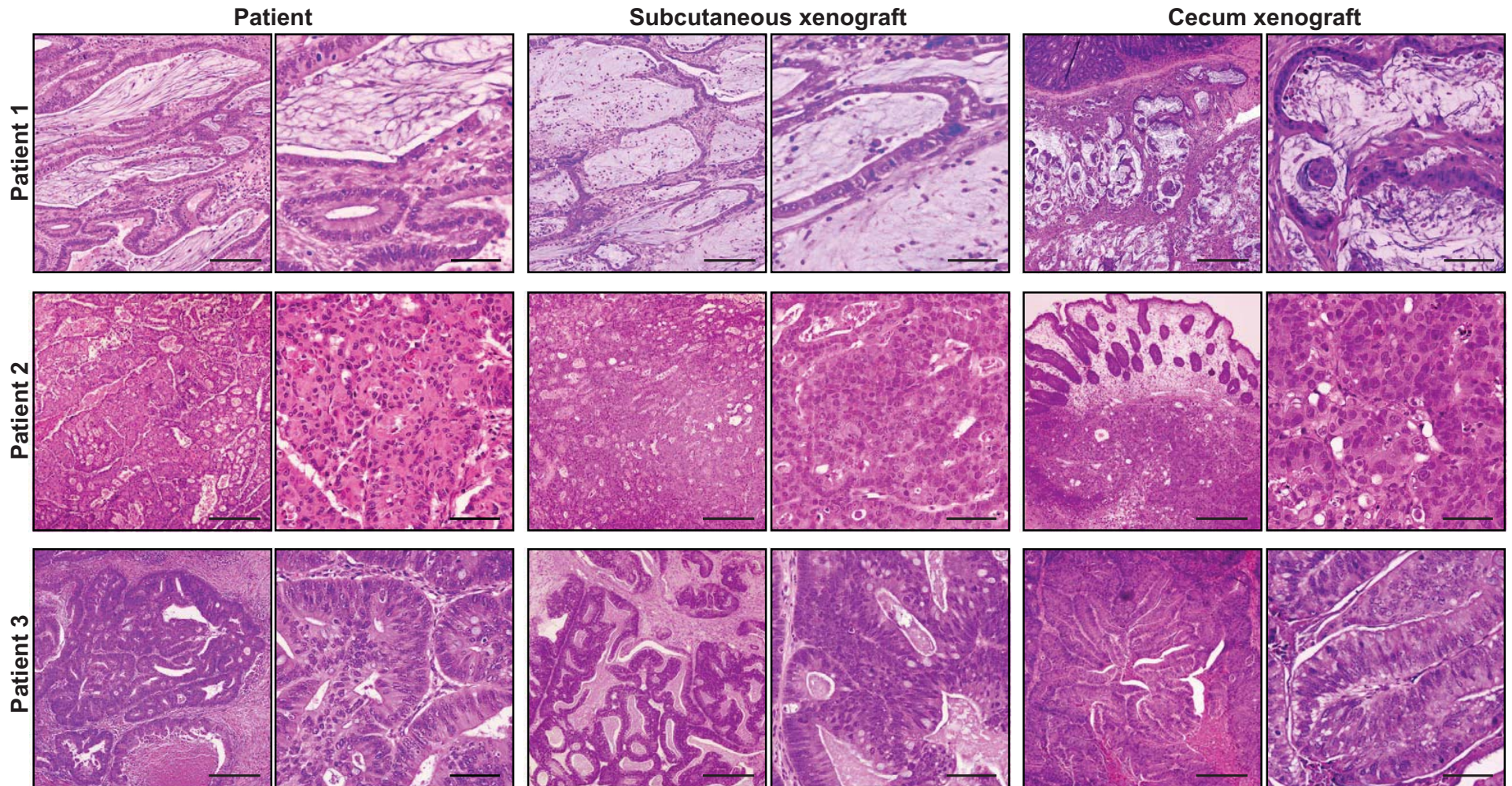
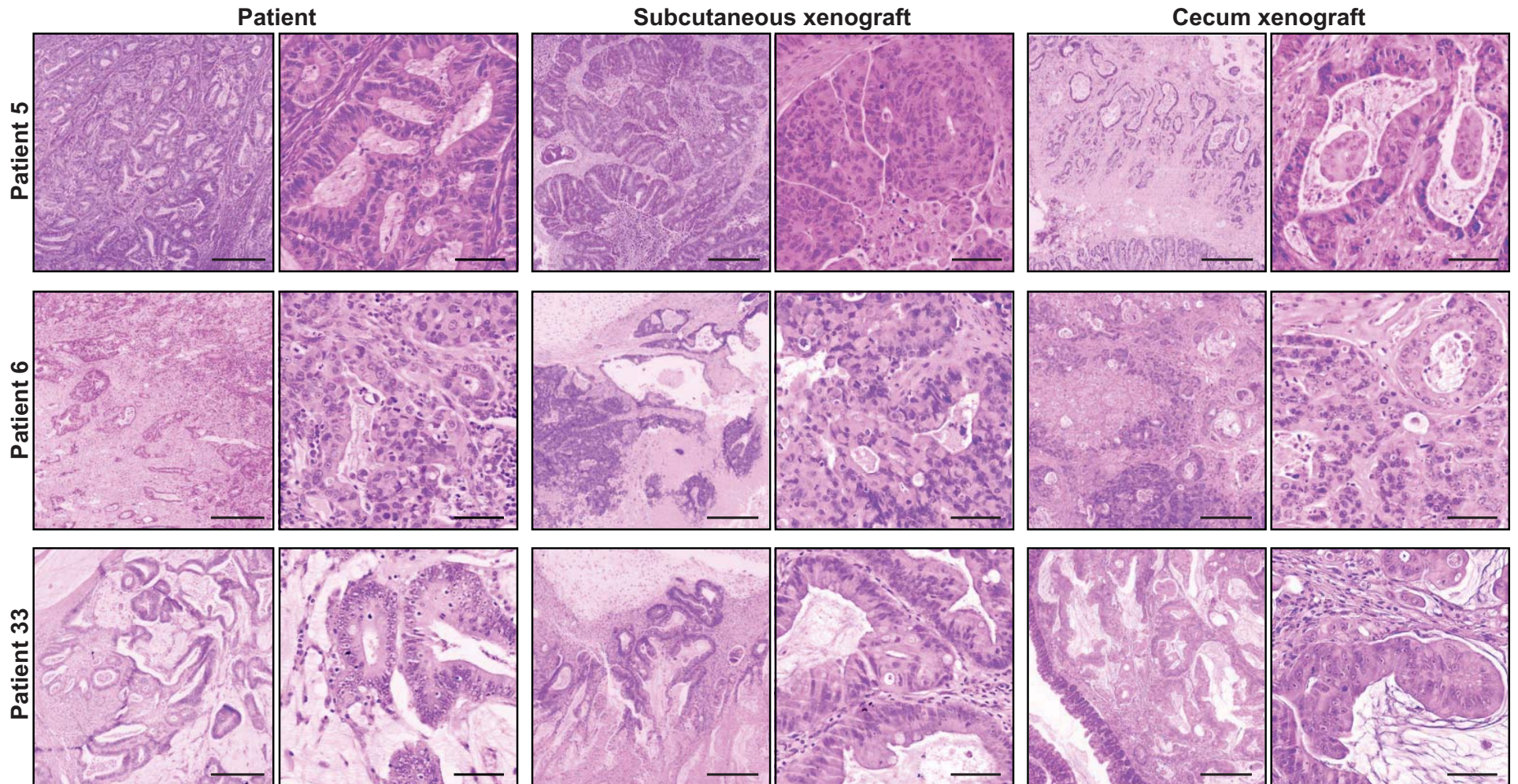


## SUPPLEMENTARY FIGURE 1A



Supplementary figure 1. Histological characterization of patients' carcinomas and the correspondent xenograft tumors. Representative pictures of Haematoxylin/Eosin staining of the primary colon carcinomas from patients 1, 2 and 3 (A) or 5, 6 and 33 (B) and their corresponding subcutaneous or cecum xenografts grown in NOD-SCID mice. Scale bar, 1 mm (columns 1, 3, 5) and 200  $\mu$ m (columns 2, 4, 6).

## SUPPLEMENTARY FIGURE 1B



Supplementary figure 1. Histological characterization of patients' carcinomas and the correspondent xenograft tumors. Representative pictures of Haematoxylin/Eosin staining of the primary colon carcinomas from patients 1, 2 and 3 (A) or 5, 6 and 33 (B) and their corresponding subcutaneous or cecum xenografts grown in NOD-SCID mice. Scale bar, 1 mm (columns 1, 3, 5) and 200  $\mu$ m (columns 2, 4, 6).