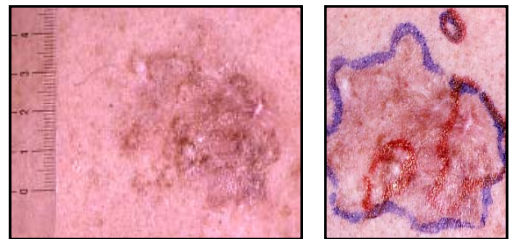
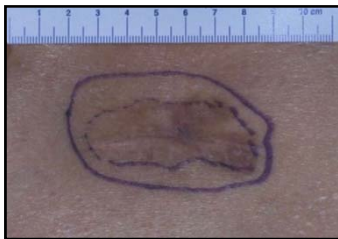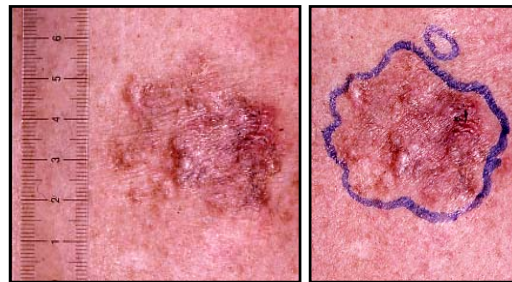
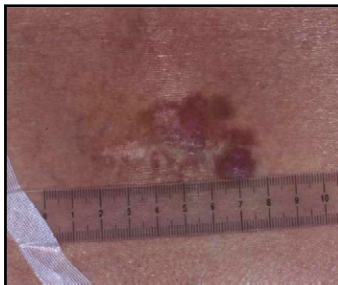


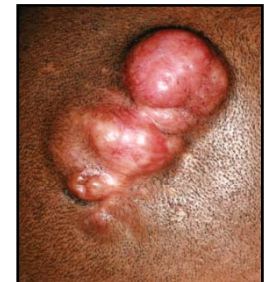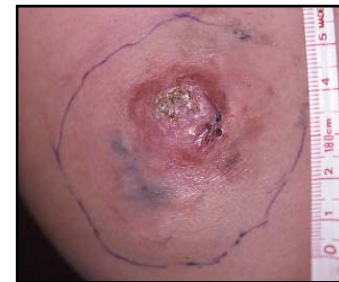# Supplementary Figure 1: clinical stable disease (SD) and partial response (PR)

SD in 2 patients with partial desinfiltration of the plaque

PR in 2 patients with nodular lesions



MO



M2

