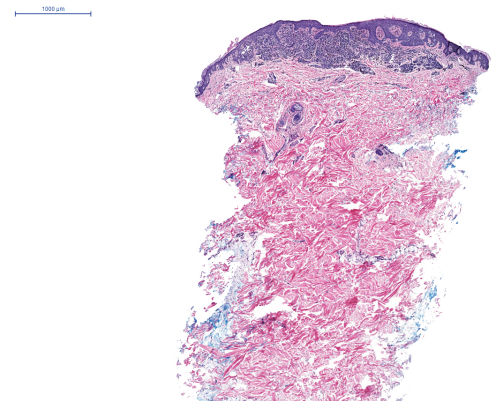
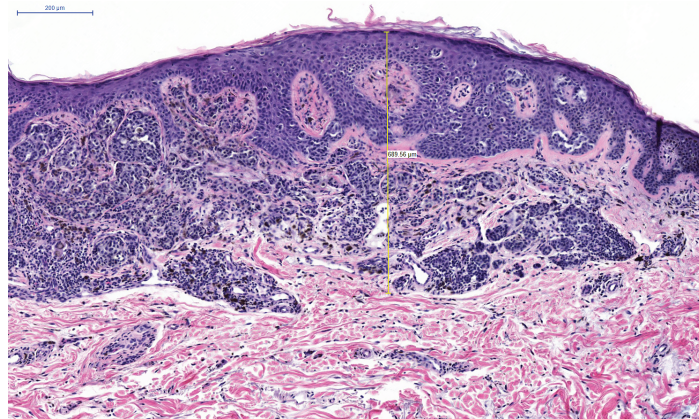


Supplemental Figure 2. This lesion from the right upper back of a 71 year old male was classified as a superficial spreading melanoma ex nevus (Breslow thickness 0.69 mm, mitotic index 1/mm², ulceration absent). The score was +4.1 Metastases to the soft tissue of the right neck developed 16 months after initial diagnosis.

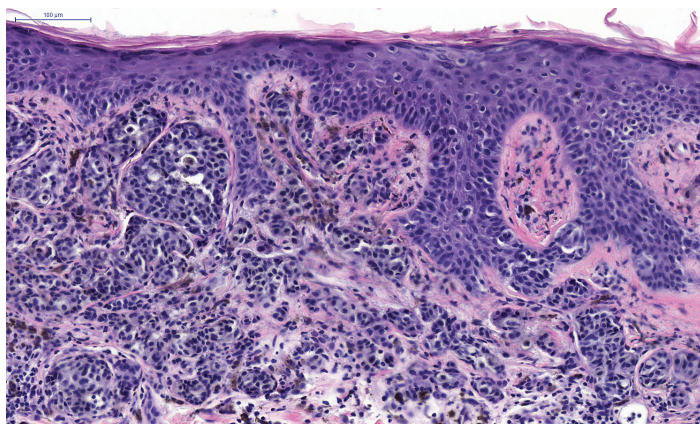
A.



B.



C.



D.

