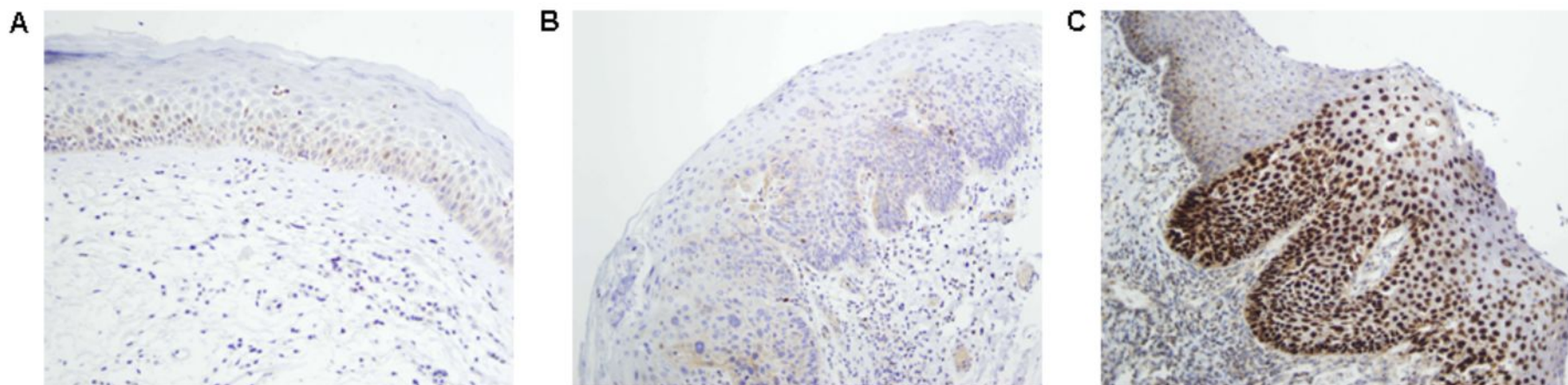


Supplementary Data Figure S4



Immunohistochemical analysis of CCND1 expression in laryngeal dysplasias. Normal adjacent epithelia showed negative staining (A). Representative examples of laryngeal dysplasias showing negative (B) and positive nuclear staining (C). Original magnification x200.